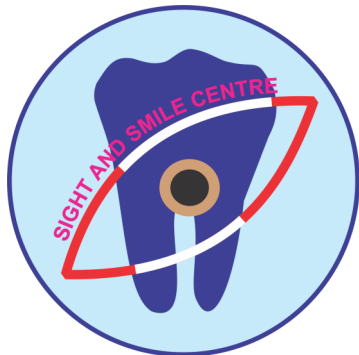

About Sight and Smile Centre

Sight and Smile Centre is a state-of-the-art eye and dental care facility established in 2008 in the heart of the Indian capital, New Delhi with the aim of providing world-class healthcare services at affordable costs to all sections of society. Located in Central Delhi, 100 metres from the Patel Nagar Metro station (on the blue line of the Delhi Metro transit system), the facility is also easily approachable by road. Vehicle parking facility is available. Spread over an area of 7200 sq ft, the centre is fully air-conditioned and has an elevator facility for patient convenience. It complies with all fire safety regulations. The comforting ambience, the warm atmosphere and cleanliness make it stand apart. Medical records of patients are maintained for future reference. The facility prides itself in having a fully-equipped ultra-modern eye operation theatre, which is one of the largest in the city. The centre is registered with the Directorate of Health, Govt. of NCT of Delhi and functions from 9 am to 9 pm (Monday - Saturday). Emergency services can be availed round-the-clock. Dr. Pankaj Malik heads the eye department while Dr. Jyoti Malik heads the dental department. It is our constant endeavour to provide such preventive and restorative services to patients that they have the best of sight and smile.



Website: www.sightandsmilecentre.com

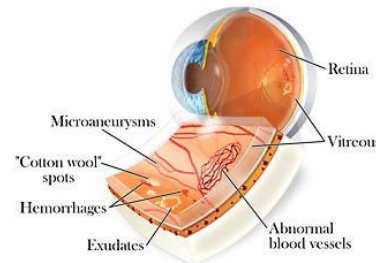
Address: 3/29, West Patel Nagar, New Delhi-110008
Tel: 011-25882945

24 hours helpline: 0-85-0605-0705
E-mail: info@sightandsmilecentre.com

DIABETIC RETINOPATHY

The silent vision stealer

Get a retina eye examination done



to see what diabetes is doing here

Diabetes can cause blindness

Protect your vision
before
it's too late

Patient Information Brochure • Not valid for legal purposes

About the retina and vitreous

Retina is the light-sensitive innermost layer of the eye on which the image of whatever we see falls. It can be divided into two regions: the central (macula) and the peripheral. The macula is an area measuring around 5.5 mm in diameter and is responsible for central vision. Tasks such as reading, writing and sewing are accomplished with the help of the macula. The peripheral retina is responsible for side (peripheral) vision. **Vitreous is a clear, jelly-like fluid which fills the space between the retina and lens and maintains the shape of the eyeball.**

About diabetes

Diabetes is a metabolic disorder in which there are high blood sugar levels over a prolonged period. It is either due to diminished insulin production from the pancreas or inability of the cells to respond properly to the insulin produced. It usually affects adults after the age of 40 years but is increasingly being diagnosed at an early age owing to faulty lifestyle.

The classic symptoms of untreated diabetes are weight loss, increased thirst, increased hunger and frequent urination. Uncontrolled diabetes can affect the heart, nerves, kidneys and eyes.

The usual symptom reported in the eye is blurred vision which may be due to cataract, glaucoma or retinal involvement.

What is diabetic retinopathy?

Diabetic retinopathy refers to retinal damage caused as a result of diabetes. Damage to the retinal blood vessels is at the core of diabetic retinopathy.

How does diabetes damage the retina?

High blood sugar causes the retinal blood vessels to become leaky and ooze out fluid which accumulates at the macula causing macular swelling (edema). Oxygen supply and nourishment to the retina is compromised. In an attempt to increase the oxygen supply, abnormal new vessel growth takes place. However, such vessels are fragile, leak blood and are the source of retinal and vitreous hemorrhage which can cause sudden loss of vision.

Symptoms of diabetic retinopathy

- Blurred, double or distorted vision.
- Reduced central vision.
- Difficulty in reading.
- Black spots (floaters) or cobwebs in one's vision.
- Shadow or veil across the field of vision.
- Partial or total loss of vision.

In the early stages of diabetic retinopathy, there are hardly any symptoms. Herein lies the importance of getting an eye examination done regularly so that treatment can be initiated on first detection of retinal changes and vision loss prevented.



Normal vision



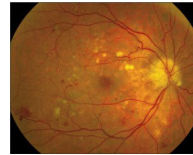
Vision in diabetic retinopathy

Who are at risk for developing diabetic retinopathy?

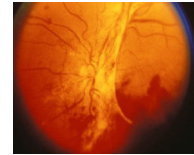
All people with diabetes are at risk for developing diabetic retinopathy. The longer someone has diabetes, the more likely he or she will develop diabetic retinopathy. Poor control of blood sugar levels hastens the onset and progression of diabetic retinopathy.

How does diabetic retinopathy progress?

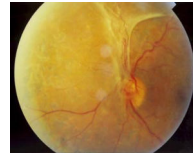
The earliest manifestation of diabetes on the retina is in the form of non-proliferative diabetic retinopathy (NPDR). It is usually asymptomatic until macular swelling (edema) occurs and causes a decrease in vision. Severe NPDR is indicative of major retinal blood vessel damage which compromises the oxygen supply to the retina and increases the risk of development of abnormal, new blood vessels in the retina. Such **new vessel growth heralds the onset of proliferative diabetic retinopathy (PDR).** PDR can lead to intraocular hemorrhage, glaucoma and retinal detachment.



NPDR



PDR

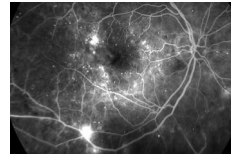


Retinal detachment in diabetic retinopathy

Specialized tests for diabetic retinopathy

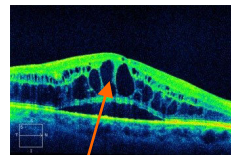
Despite regular eye examination which includes visual acuity assessment, measurement of intraocular pressure (IOP) and direct visualization of the retina, specialized tests may need to be performed to better define the stage of diabetic retinopathy, plan treatment protocols and assess treatment response.

- ♦ **Fundus Fluorescein Angiography (FFA):** FFA involves injecting a fluorescent dye (Sodium fluorescein) into a vein in the arm. As the dye passes through the retinal blood vessels, photographs of the retina in colour as well as in black and white format are taken in rapid succession. FFA photographs capture the details of dye leaking from abnormal blood vessels and also show areas of the retina deficient in oxygen.



FFA in diabetic retinopathy

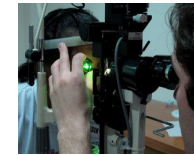
- ♦ **Optical Coherence Tomography (OCT):** OCT is a new non-invasive imaging technique which provides a high resolution cross-sectional view of the retina and helps in quantifying the amount of macular edema.



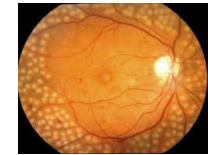
Macular edema in diabetic retinopathy

Treatment options in diabetic retinopathy

- ♦ **Laser photocoagulation:** Laser photocoagulation functionally destroys the less oxygenated areas of the retina where abnormal blood vessel growth takes place. This causes the abnormal vessels to regress and swelling to subside. Laser regimen is usually completed in multiple sessions and benefits take 3-4 months to accrue. When laser is done in areas away from the macula, the procedure is called pan-retinal photocoagulation (PRP). Focal or grid photocoagulation is done for macular edema. Laser treatment can help to maintain one's vision and prevent further deterioration. It is a walk-in, walk-out procedure and does not involve any hospital stay.



Laser photocoagulation



Laser scars

- ♦ **Pars Plana Vitrectomy (PPV):** PPV is a surgical procedure performed in cases of persistent vitreous hemorrhage or tractional retinal detachment. It involves removal of blood and scar tissue from the vitreous cavity and is often supplemented by intra-operative laser photocoagulation (endo-laser). Many patients have improved vision following PPV.
- ♦ **Intravitreal injections:** Injections of vascular endothelial growth factor (VEGF) inhibitor drugs or steroids are given into the vitreous cavity of the eye in order to reduce macular edema or reduce abnormal vessel growth and bleeding. They may also be used prior to surgery.

Vision lost due to diabetic retinopathy cannot be restored but further visual loss can be prevented by the above treatment measures. Patients must maintain proper blood sugar levels as this measure can delay the onset and limit the progression and complications of diabetic retinopathy.