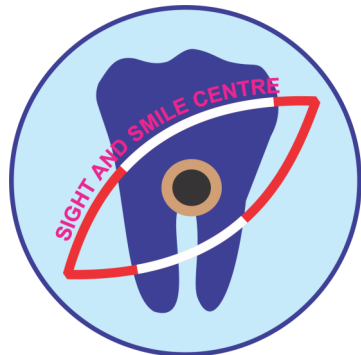


About Sight and Smile Centre

Sight and Smile Centre is a state-of-the-art eye and dental care facility established in 2008 in the heart of the Indian capital, New Delhi with the aim of providing world-class healthcare services at affordable costs to all sections of society. Located in Central Delhi, 100 metres from the Patel Nagar Metro station (on the blue line of the Delhi Metro transit system), the facility is also easily approachable by road. Vehicle parking facility is available. Spread over an area of 7200 sq ft, the centre is fully air-conditioned and has an elevator facility for patient convenience. It complies with all fire safety regulations. The comforting ambience, the warm atmosphere and cleanliness make it stand apart. Medical records of patients are maintained for future reference. The facility prides itself in having a fully-equipped ultra-modern eye operation theatre, which is one of the largest in the city. The centre is registered with the Directorate of Health, Govt. of NCT of Delhi and functions from 9 am to 9 pm (Monday - Saturday). Emergency services can be availed round-the-clock. Dr. Pankaj Malik heads the eye department while Dr. Jyoti Malik heads the dental Department. It is our constant endeavour to provide such preventive and restorative services to patients that they have the best of sight and smile.



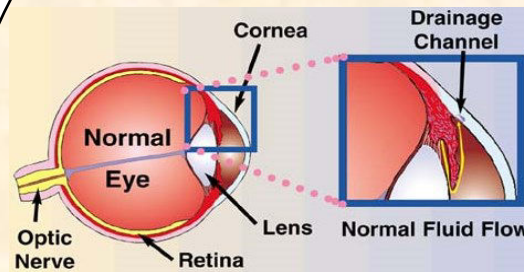
Website: www.sightandsmilecentre.com

Address: 3/29, West Patel Nagar, New Delhi-110008
Tel: 011-25882945
24 hours helpline: 0-85-0605-0705
E-mail: info@sightandsmilecentre.com

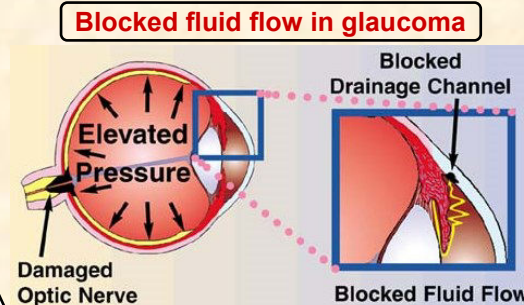
GLAUCOMA

The silent vision snatcher

Yearly eye check-up can help in early detection of glaucoma



Fluid flow in normal eye



Blocked fluid flow in glaucoma

What is glaucoma?

Glaucoma (Hindi: Kala Motia) is a serious, vision threatening condition in which there is increased intraocular pressure (IOP) that damages the nerve fibres of the optic nerve. Since the optic nerve is responsible for carrying visual messages to the brain, its damage, if uncontrolled, results in progressive vision loss.

The pathology of glaucoma

A fluid known as aqueous humour is formed inside the eye and nourishes its front part. It drains through the trabecular meshwork, a network of drainage canals located around the edge of the iris, the coloured part of the eye. In a normal eye, the rate of aqueous production and its drainage are matched such that the eye pressure is maintained in a normal range of 12-21mm Hg.

Factors such as increasing age, disease, trauma tend to block these drainage channels and the fluid cannot drain out of the eye. This causes a build-up of fluid inside the eye leading to increase in eye pressure. The sensitive nerve fibres which make up the optic nerve cannot withstand the increased pressure and begin to die out. The process is usually very slow and silent but irreversible. Usually the peripheral vision is lost first. Eventually central vision is lost and blindness ensues.

Risk factors for glaucoma

- ◆ Age above 40 years.
- ◆ Family history of glaucoma.
- ◆ High intraocular pressure.
- ◆ Farsightedness or nearsightedness.
- ◆ Medical conditions such as diabetes and hypertension.
- ◆ Secondary to conditions such as cataract or eye inflammation.
- ◆ Prior eye surgery.
- ◆ Chronic steroid use.


Types of glaucoma

- ◆ **Open angle glaucoma:** It is the most prevalent type of glaucoma and causes gradual, painless loss of vision, although initially asymptomatic. It occurs when the drainage channels of the eye get blocked internally although the entrance to the channels (angle of the eye) is open.

- ◆ **Closed angle glaucoma:** It is also called acute or narrow-angle glaucoma. It occurs when the entrance to the drainage channels (angle of the eye) itself is blocked / narrowed. The IOP rises very quickly and is accompanied by eye pain, redness, headache, nausea, vomiting, coloured haloes around lights and blurred vision.
- ◆ **Normal tension glaucoma:** In this type of glaucoma, optic disc damage occurs even though the IOP is within the normal range. A potential risk factor for normal tension glaucoma is decreased blood flow into the eye.
- ◆ **Congenital glaucoma:** This type of glaucoma affects children and newborns. A defect in the angle of the eye retards drainage of aqueous humour out of the eye. Symptoms are large eyes, cloudy eyes, sensitivity to light and excessive watering.
- ◆ **Secondary glaucoma:** This group includes glaucoma occurring secondary to medical conditions such as mature cataract, eye inflammation, intraocular bleeding, previous eye injury and chronic steroid use.

Symptoms of glaucoma

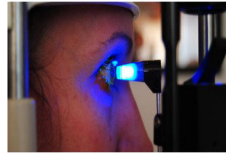
- **Painless, gradual loss of vision.**
 - ▶ Since only the peripheral vision is lost initially, the patient may not notice the vision loss until central vision is affected. By the time medical attention is sought, advanced stages of the disease have set in and extensive optic disc damage and visual impairment have occurred.
- Difficulty in adjusting vision on entering a darkened room.
- Pain around the eyes, especially in dim light.
- Redness / Watering of the eye.
- Coloured haloes around lights.
- Frequent change of reading glasses.
- Headache.



Peripheral visual field loss Coloured haloes around lights

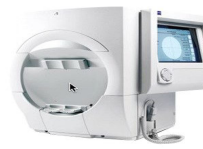Diagnostic modalities in glaucoma

- ◆ **Tonometry:** The tonometry test measures the intraocular pressure (IOP). Applanation tonometry is the gold standard test for measuring IOP. The surface of the eye is numbed with anaesthetic eye drops and IOP measured by Goldmann's applanation tonometer. Now-a-days, a 24 hour, smart continuous monitoring of IOP has become feasible with triggerfish contact lenses.



Applanation tonometry

- ◆ **Gonioscopy:** Gonioscopy is the procedure by which the drainage system at the angle of the eye can be inspected. After numbing the eye with anaesthetic eye drops, a special lens called the gonioscope is brought in contact with the front of the eye and looking through the lens, the angle is visualized. Gonioscopy helps to detect the type of glaucoma, open angle or closed angle, based on whether the angle is found to be open or closed.
- ◆ **Ophthalmoscopy:** An ophthalmoscope having an inbuilt light source is used to examine the inside of the eye, particularly the optic disc, for damage caused by glaucoma.
- ◆ **Autoperimetry:** Autoperimetry is a procedure which analyses the visual field of each eye. The patient, with the seeing eye fixed at a central target in an illuminated bowl-shaped area in the autoperimeter, is required to press and immediately release a hand-held switch device on seeing a small light dot appearing randomly across the area. Each eye examination takes 10-15 minutes to perform. The test analyses the extent of visual field defects in glaucoma as well as disease progression and treatment response.



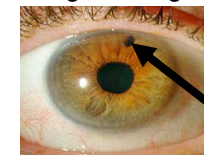
Autoperimeter

- ◆ **Optical Coherence Tomography (OCT):** The retinal nerve fibres converge to form the optic disc which represents the beginning of the optic nerve. Retinal nerve fibre layer (RNFL) thinning is the earliest change to occur in glaucoma, much before changes are observed in the optic disc. OCT is a new modality of analysis of the retinal nerve fibre layer. In OCT, a contour map of the optic cup and RNFL is created by use of special beams of light.

Management options in glaucoma

Management of glaucoma centres around reduction of IOP to a desired target level within the normal range where it can limit further damage to the nerve fibres of the optic nerve. Glaucoma can be controlled by medicines, laser, surgery or a combination of these.

- ◆ **Medicines:** Medicines in the form of eye drops or pills are the most commonly prescribed treatment for glaucoma. Treatment is life-long.
- ◆ **Laser:** Laser treatment is often suggested when IOP control with medicines is not adequate. Selective laser trabeculoplasty (SLT) involves treating the trabecular meshwork with laser in order to enhance fluid drainage. The laser acts by stretching the drainage channels. YAG laser peripheral iridotomy (YAG PI) is a procedure in which an alternative opening is created in the iris by the laser to allow drainage of stagnant aqueous fluid which has been mechanically blocking the angle of the eye.



YAG PI

- ◆ **Surgery:** Conventional glaucoma filtering surgery involves making a new drainage pathway for the fluid to leave the eye thereby bypassing the blocked drainage channels. Sometimes, artificial drainage devices are implanted during surgery for controlling fluid filtration rates. Surgery is usually required when medicines and laser are no longer able to control the IOP adequately.